

# CASE REPORT ON THE USE OF MLC 601 (NEUROAID®) IN NEUROSURGICAL PATHOLOGIES

Assoc. Prof. Yeo Tseng Tsai<sup>(1)</sup>  
Assoc. Prof. Chou Ning<sup>(2)</sup>

(1) FRACS (Neurosurgery); FAMS; Senior Consultant Neurosurgeon, National University Hospital, Singapore  
(2) FRCS (Neurosurgery); FAMS; Head of Neurosurgery Division, National University Hospital, Singapore

## INTRODUCTION

Head injury is in fact the commonest cause of trauma mortality [1]. Similarly, hemorrhagic stroke is the deadliest and the least treatable form of stroke [2], with over one third of the victims dying within 1 month of symptom onset, and most survivors never regain functional independence [3].

MLC601 (NeuroAid®) is a medication that originates from Traditional Chinese Medicine (TCM), and has been developed for post ischemic stroke recovery. It combines 9 herbal and 5 animal components [4]. Previous studies have proved its efficacy and safety [4, 5, 6, 7, 8].

MLC601's role in preventing neuronal death in an *in vitro* model of excitotoxicity using primary cultures of cortical neurons exposed to glutamate has recently been established. In addition MLC601 treatments were shown to induce neurogenesis in rodent and human cells, promote cell proliferation as well as neurite outgrowth and stimulate the development of a dense axonal and dendritic network [9]. These data further support the assumption that MLC601 could be beneficial in neurosurgical pathologies.

## OBJECTIVE

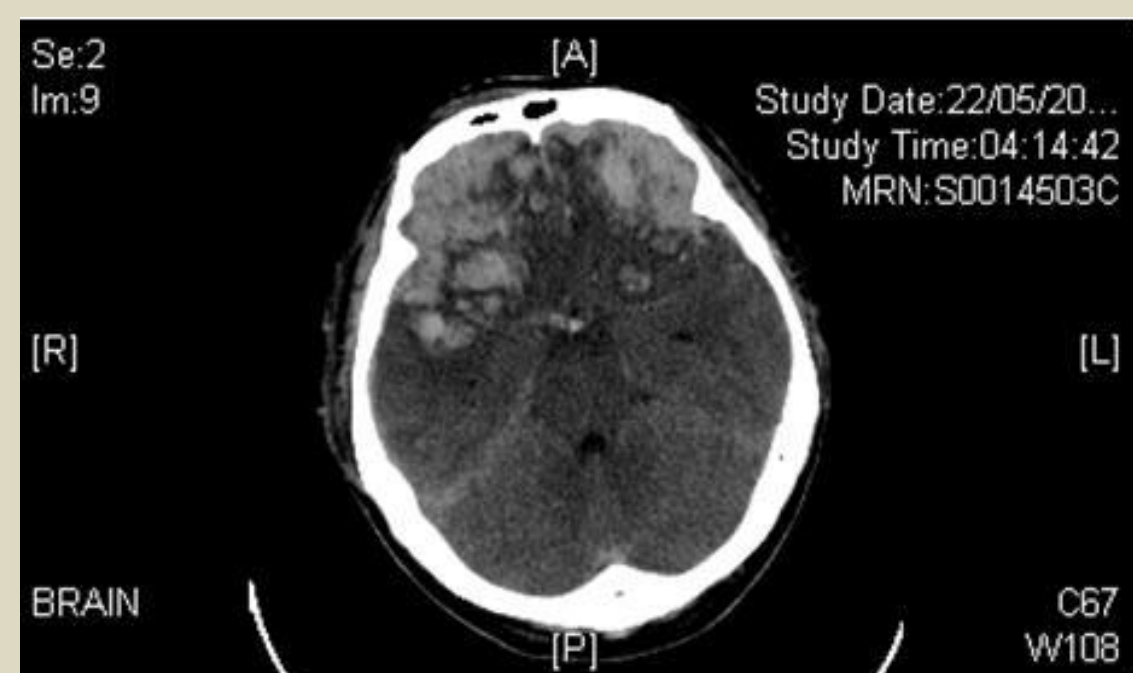
To date most reported clinical evidence on MLC601 has to do with neurological rather than neurosurgical pathology.

## METHODS

More than 20 patients were treated with MLC601 in the Neurosurgery division of National University Hospital in Singapore. All patients received 4 capsules of MLC601 3 times a day for a duration of 3 months and within 3 months of onset of brain injury or stroke. The patients all reported some improvements. We report here our early positive anecdotal experience using MLC601 in 3 patients.

## CASE REPORT

### Patient 1 (Head Injury)



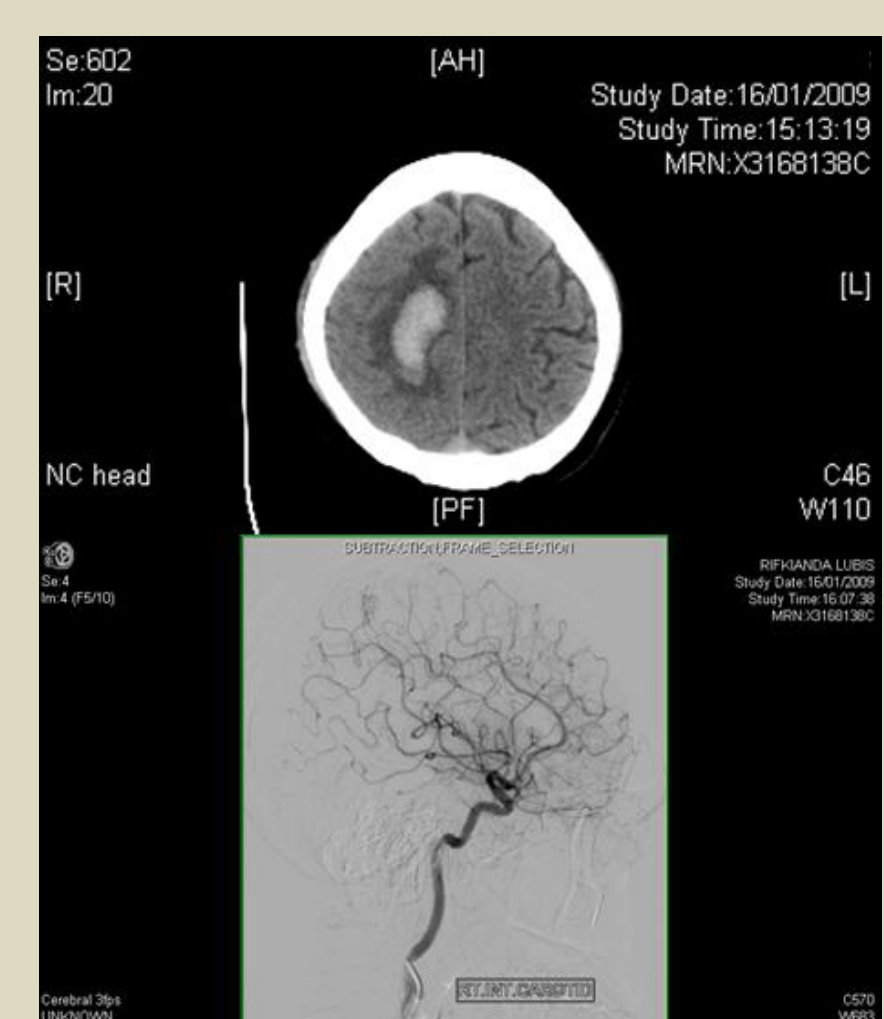
55-year old male admitted for contracoup head injury after falling at home and hitting the back of his head. The Glasgow Coma Scale (GCS) was 13 on admission quickly deteriorated to 7 within the next 4 hours. CT scan showed bifrontal contusions with mass effect (Fig. 1).

**Treatment** Large decompressive craniectomy, an evacuation of the hemorrhagic contusions. Induction of barbiturate coma but eventually normalized after a week. The patient developed multiple infections with high fever and had to be treated with multiple antibiotics. A tracheostomy was done.

*Started MLC601 one month after the head injury for 3 months.*

**Outcome** Within 4 weeks of commencing MLC601 treatment, he improved from a vegetative state to conversing in three languages he spoke initially. After 6 weeks of MLC601 therapy and an intensive program in rehabilitation hospital he however finally was able to ambulate with some help.

### Patient 2 (Hemorrhagic Stroke)



43-year old male admitted for sudden onset left sided weakness and numbness. Neurological assessment showed that his left lower limb strength was essentially 0/5 but his left upper limb strength was 4/5. CT scan revealed a right fronto-parietal 5.5 cm diameter hemorrhage (Fig. 2). The cerebral angiogram showed a small frontal parafalcine arterio-venous malformation (AVM) to be cause of the hemorrhagic stroke. Gamma knife radiosurgery was performed to treat the AVM definitively.

*Underwent a standard rehabilitation therapy and started MLC601 3 weeks after brain hemorrhage.*

**Outcome** After one week of treatment, very noticeable improvement was observed and his left upper limb had recovered to 4+/5 while his left lower limb function had recovered to 3/5. After 1 month of MLC601 treatment, power of the left sided limbs had improved to 5/5 in both upper and lower limbs (except for the ankle dorsiflexion which remained at 4+/5 power).

### Patient 3 (Brain Abscess)

39-year old Indonesian with a history of progressive headaches for the last 2 months. CT scan showed left frontal lobe brain abscess and he underwent aspiration of the abscess followed by intravenous antibiotics in Indonesia. He however didn't improve clinically and his condition continued to deteriorate and he remained in deep coma post-op requiring intubation and mechanical ventilation. His Glasgow Coma Scale 6 on arrival in Singapore and remained in critical condition post-op with a very slow progressive recovery for the first month and still remained semi comatose (Glasgow coma scale 9)

**Treatment** He underwent emergency excision of the large recurrent brain abscess in Singapore followed by a long course of intravenous vancomycin (the culture from the pus from the brain abscess grew Staph aureus). He required a tracheotomy to be done also for prolonged intubation.

*One month after his surgery in Singapore., he started MLC601 for a total of 3 months.*

**Outcome** He was transferred to the rehabilitation hospital one week after starting MLC601 when he was noticed to have improved to a more alert state with a Glasgow Coma Scale of 13. After a total of 3 months of MLC601 therapy, he was noticed to have made a most remarkable improvement both functionally and cognitively. He was able to ambulate independently with quite a normal gait and could also converse quite normally.

## DISCUSSION

There has been a recent resurgence of interest in these products from the traditional Chinese pharmacopoeia. Several RCT are testing the efficacy of MLC601 being currently conducted to try to prove this scientifically once and for all [6, 10].

The vast majority deal with neurological pathology like ischemic strokes. The authors reasoned that based on its mode of action and clinical efficacy in the neurological realm, there is no reason why MLC601 should not work positively in some patients with desperate neurosurgical pathology. Hence our initial foray to examine the efficacy of MLC601 in a small cohort of uncontrolled anecdotal cases first. Our initial positive experience has prompted us to make this report and to take this a step further and design a RCT to prove its efficacy in basal ganglion hemorrhagic strokes in particular.

In our initial clinical experience, the oral treatment with MLC601 was very well tolerated in all our cases (and in particular for neurosurgery, no increased bleeding was seen). The three cases reported here showed exceptionally good improvement. The rehabilitation therapy performed could perhaps provide some explanation for the recovery in neurological function. However, given the speed and extent of recovery, it is the authors' opinion that the improvement is at least attributable to the MLC601 medication to some extent whose neuroproliferative and neuroprotective effects were studied *in vitro* and *in vivo* recently [9].

These three cases are anecdotal reports which hence remain only at level III evidence. Nevertheless, the authors believe that given their positive initial clinical experience and that side effects are almost nil from this naturally derived compound, it is not unreasonable to prescribe MLC601 to selected patients with difficult neurosurgical pathology like severe head injury or bad hemorrhagic strokes, amongst others, in the hope that the neurological function outcome would improve.

## REFERENCES

- MacKenzie EJ. Epidemiology of injuries: current trends and future challenges. *Epidemiol Rev* 2000; 22:112-9.
- Broderick JP, Brodt TG, Dulner JE, Tomsick T, Huster G. Volume of intracerebral hemorrhage. A powerful and easy-to-use predictor of 30-day mortality. *Stroke* 1993; 24:987-993.
- Counsell C, Boonyakarnul S, Dennis M, Sandercock P, Bamford J, Burn J, Warlow C. Primary intracerebral hemorrhage in the Oxfordshire Community Stroke Project 2. Prognosis. *Cerebrovasc Dis* 1995; 5:26-34.
- Chen C, Venketasubramanian N, Gan R, Lambert C, Picard D, Chan B, Chan E, Bousser MG, Xuemin S, Danqi Jiaonang (DJ), a Traditional Chinese Medicine, in post-stroke recovery. *Stroke* 2009; 40:859-63.
- Siow HG. NeuroAid in Stroke Recovery. *Europ Neurol* 2008; 60:264-6.
- Kong KH, Wee SK, Ng CY, Chua K, Chan KF, Venketasubramanian N, Chen C. A double-blind, placebo-controlled, randomized phase II pilot study to investigate the potential efficacy of the Traditional Chinese Medicine Neuroaid (MLC 601) in enhancing recovery after stroke (TIERS); *Cerebrovasc Dis* 2009; 28:514-21.
- Gan R, Lambert C, Lianting J, Chan E, Venketasubramanian N, Chen C, Chan B, Samama M, Bousser MG; NeuroAid/ Danqi Piantan Jiaonang does not modify hemostasis, hematology and biochemistry in normal subjects and stroke patients; *Cerebrovasc Dis* 2008; 25:450-6.
- Young SHY, Zhao Y, Koh A, Singh R, Chan B, PL, Chang HM, Venketasubramanian N, Chen C. Safety profile of MLC 601 (NeuroAid®) in acute ischemic stroke patients: A Singaporean substudy of the CHinese Medicine NeuroAid® Efficacy on Stroke recovery (CHIMES) Study. *Cerebrovasc Dis* 2010; 30:1-6.
- Heurteaux C, Gandin C, Borsotto M, Widmann C, Brau F, Lhuillier M, Onteniente B, Lazdunski M. Neuroprotective and neuroproliferative activities of NeuroAid (MLC601, MLC901), a Chinese Medicine in vitro and in vivo. *Neuropharmacol* 2010; 58: 987-01.
- Venketasubramanian N, Chen C, Gan R, Chan B, Chang HM, Tan SB, Picard D, Navarro JC, Baroque AC, Pongvarin N, Donnan GA, Bousser MG; A double-blind, placebo-controlled, randomized, multicenter study to investigate CHinese Medicine Neuroaid Efficacy on stroke recovery. *Int J Stroke* 2009; 4: 54-60.